

D.D OF LATERAL NECK SWELLINGS

PRESENTED BY

MOHAMED ABDO SALEM (18402)

MOHAMED ABD EL-MOGHNY MANDOR (18398)

MOHAMED ABD EL-MONEM ABD EL-HALEM (18399)

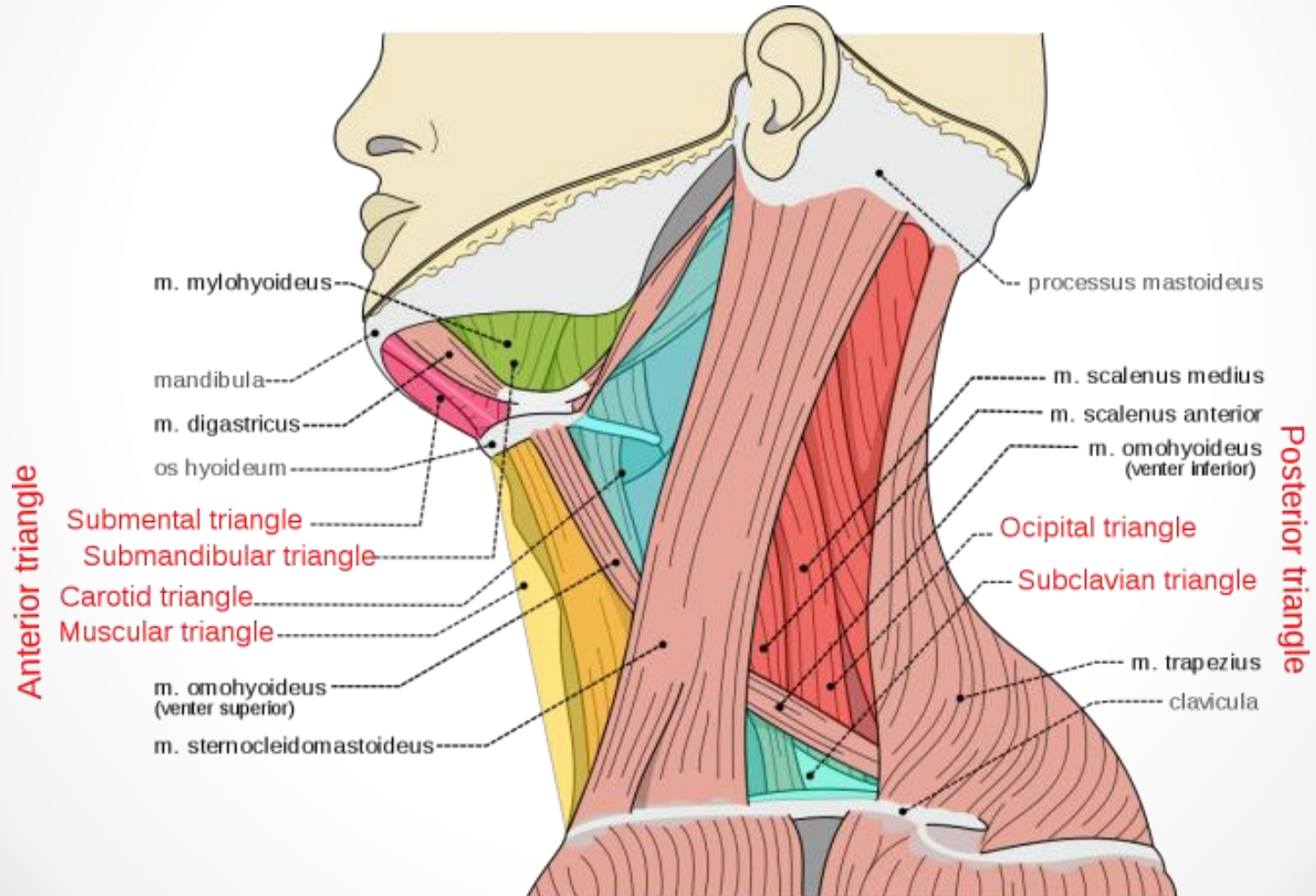
MOHAMED ABD EL-MONEM EDRES (18400)

MOHAMED ABDO EL-NAHAL (18401)

SUPERVISOR

GENERAL SURGERY DEPARTMENT EL-AZHAR UNIVERSITY

Triangles of the neck



POSTERIOR TRIANGLE SWELLINGS

Solid swellings

- Cervical rib
- Sternomastoid tumor
- Neurofibroma arising from brachial plexus

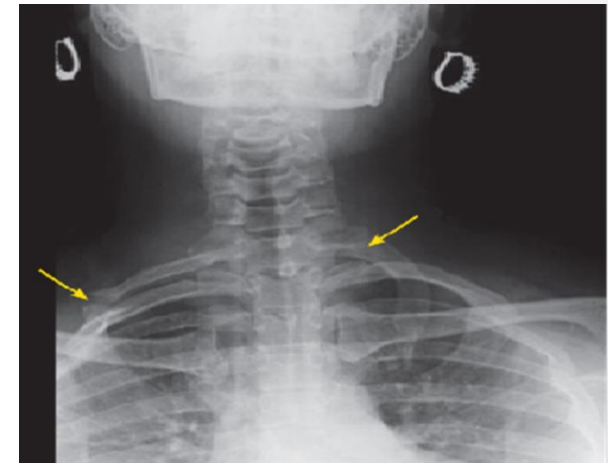
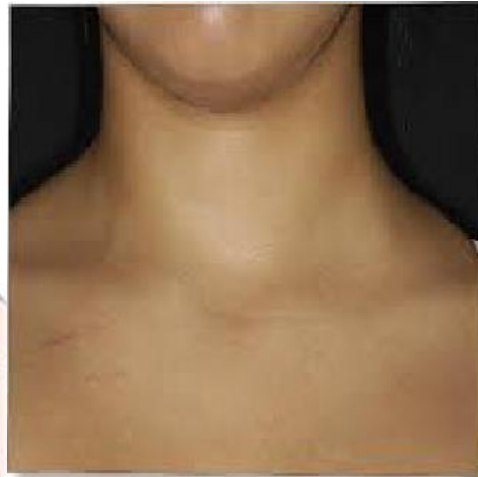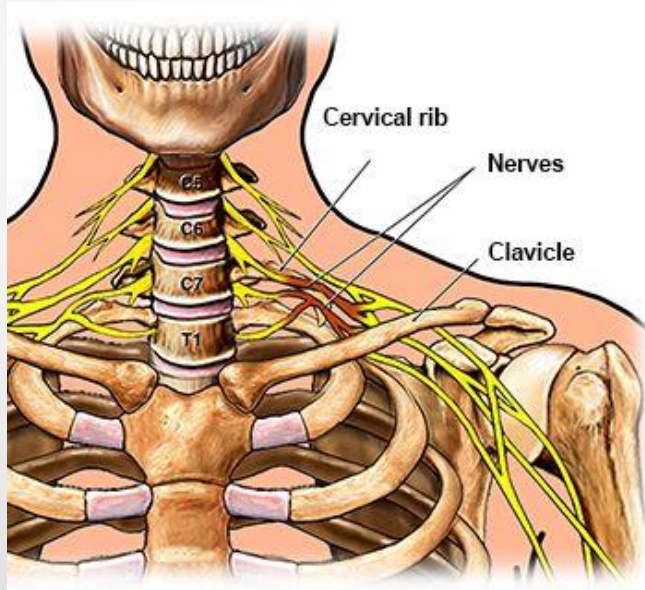
Cystic swellings

- Pharyngeal diverticulum
- Cystic hygroma

Cervical Rib

D.D: associated with tingling and numbness in the medial aspect of forearm and hand due to compression on lower root of plexus

Investigation : X-ray is diagnostic.

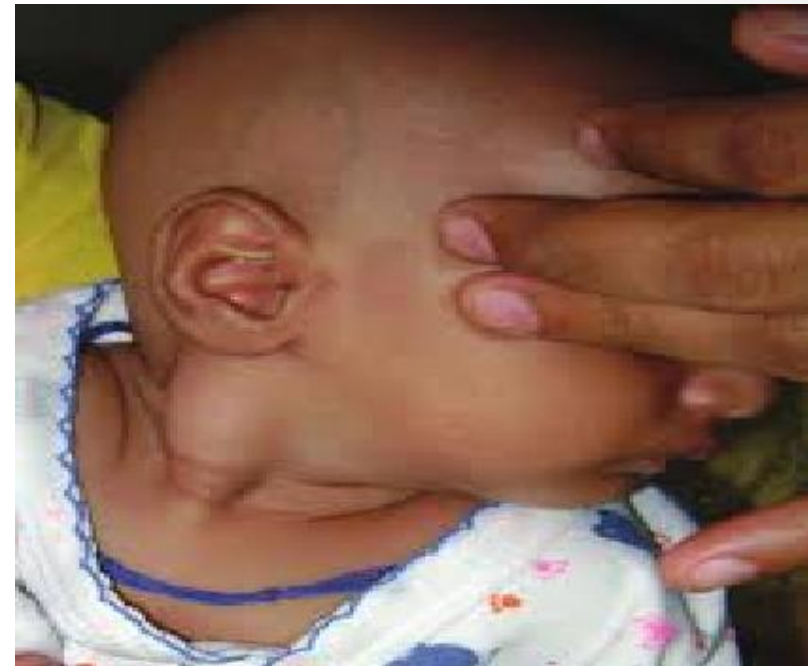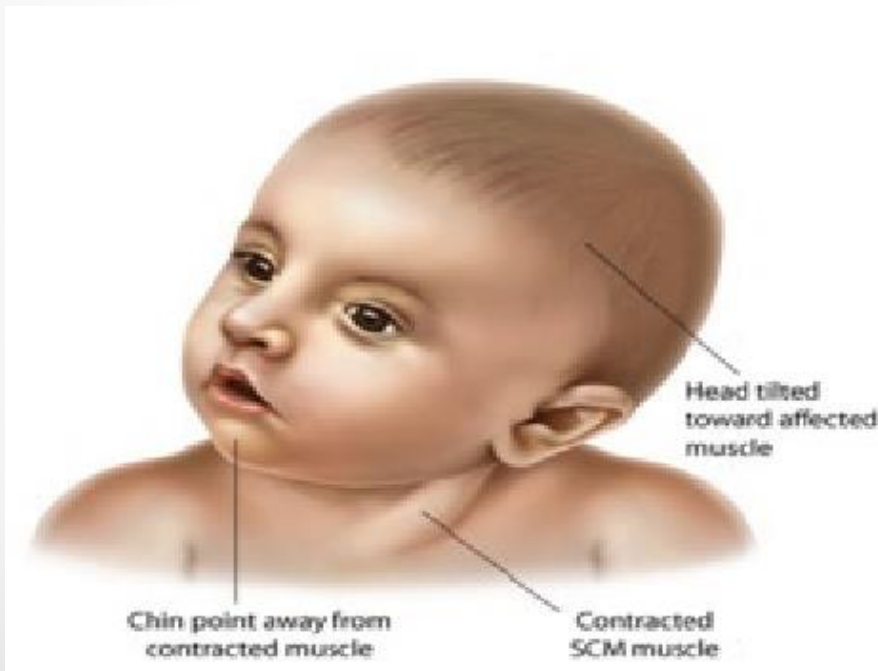


Sternomastoid tumor

D.D: •

firm swelling at thr middle portion of sternomastoid muscle. •

the head will be tilted to the side of the lesion while the face •
looking to the opposite side.

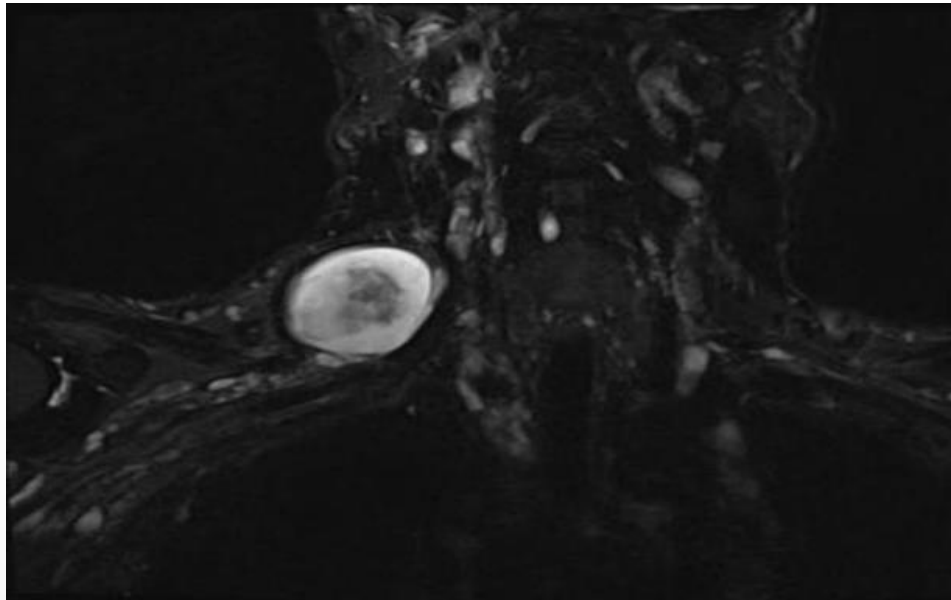


Neurofibroma of brachial plexus

C/P

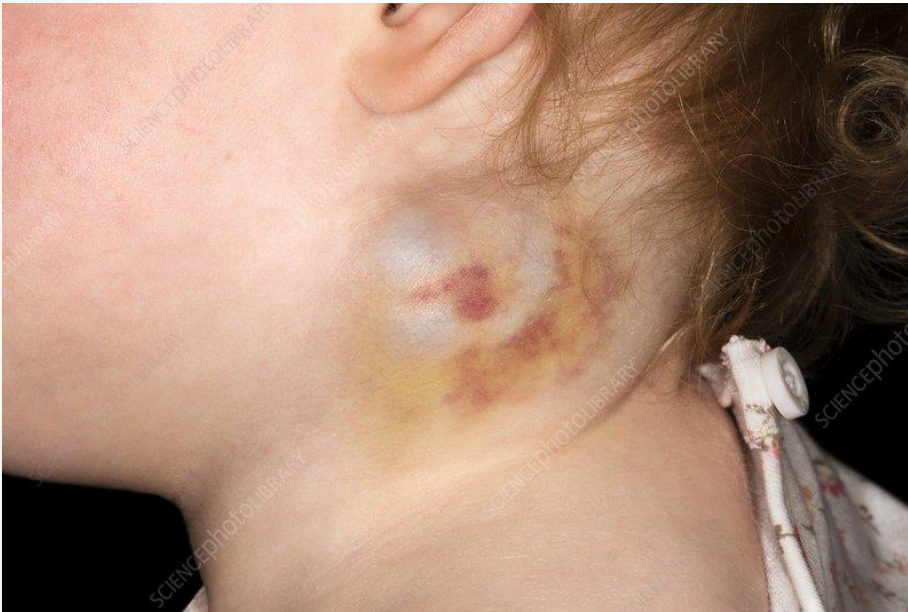The swelling is painless but tender due to pressure on affected nerve ,fusiform in shape,firm in consistency,mobile across not along the nerve.

Investigation: CT-Scan or MRI.

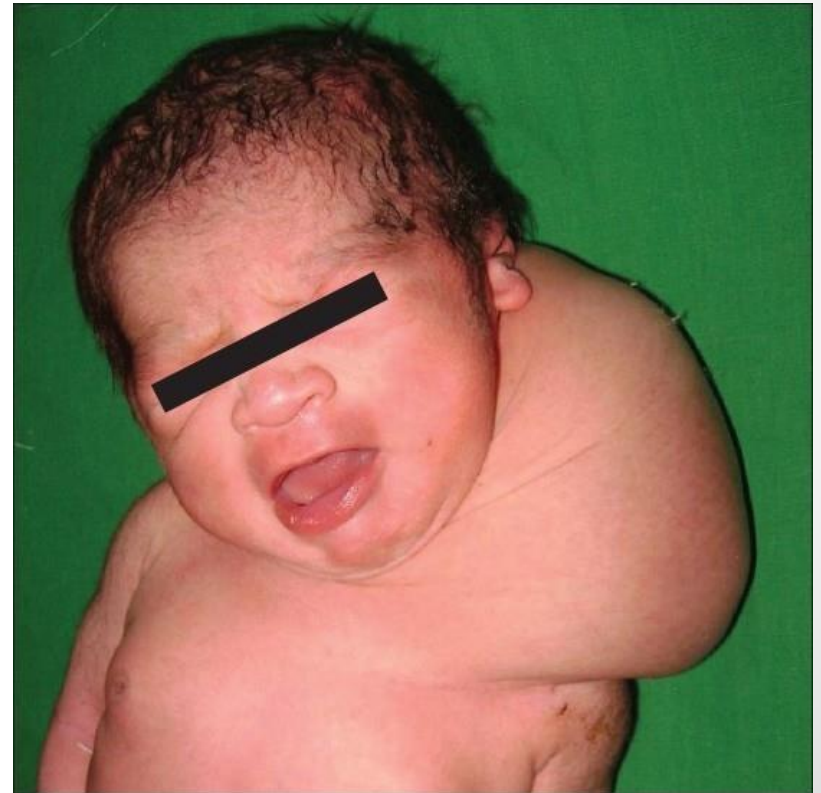

Cystic hygroma

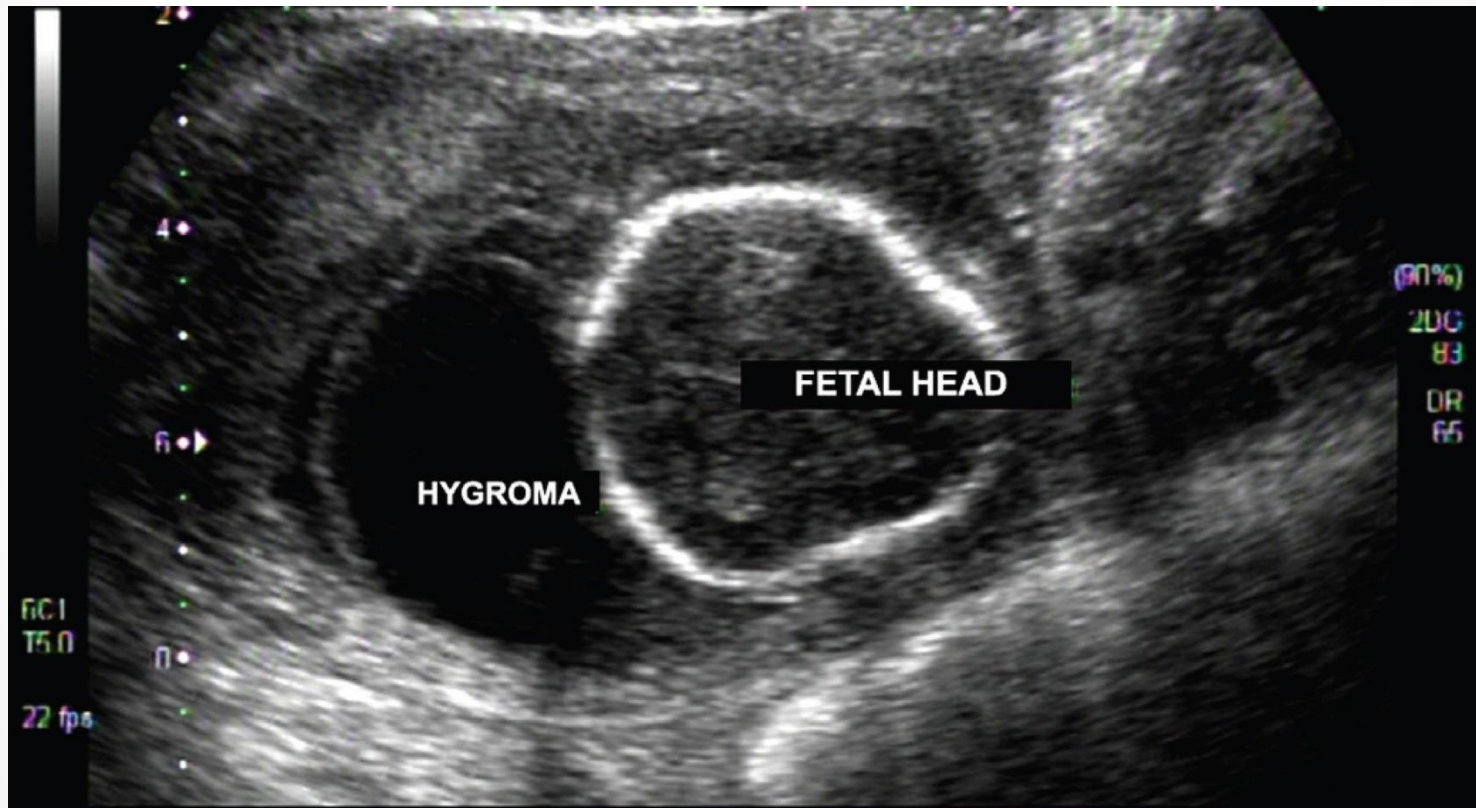
Aetiology : congenital malformation of lymph vesicles



Bluish swelling

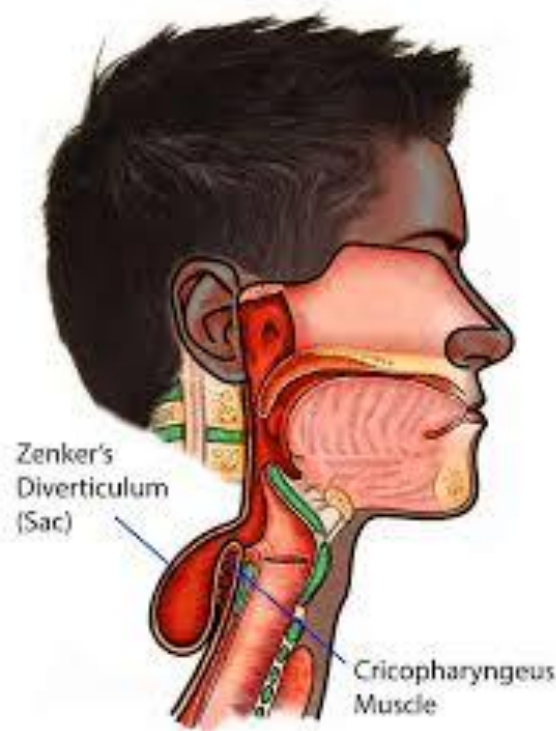


Investigation : ultrasound is diagnostic



Pharyngeal diverticulum

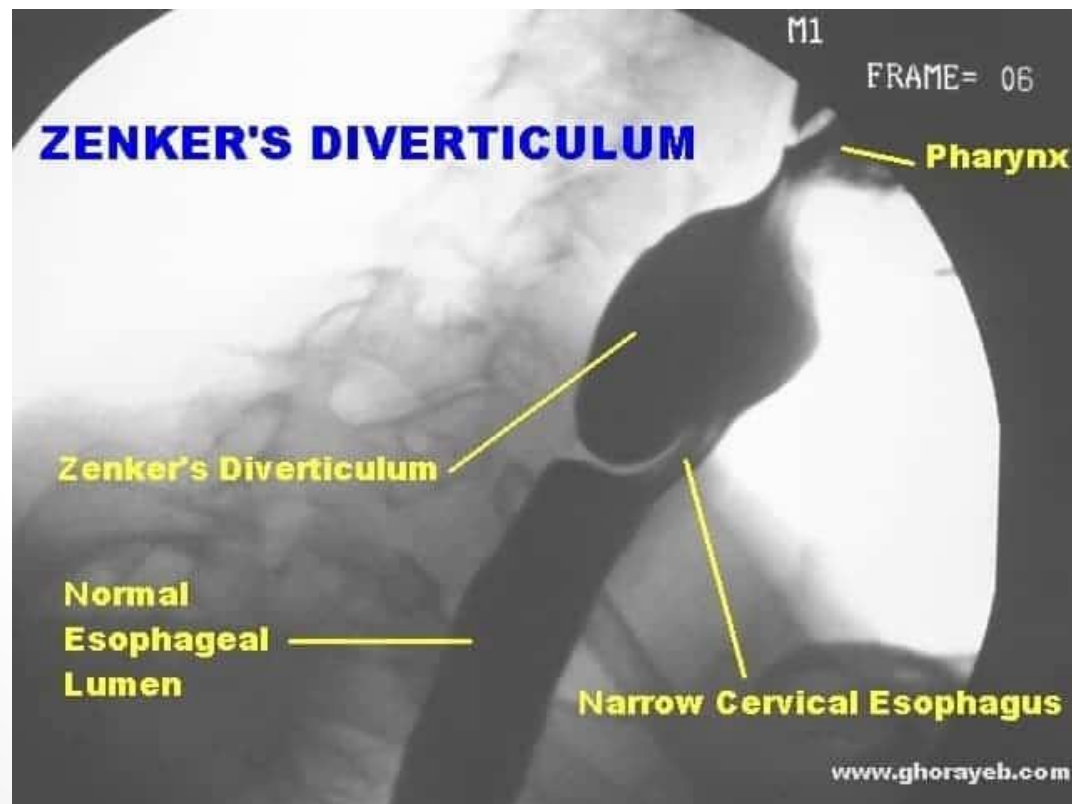
Def : Herniation of pharyngeal mucosa through a weak area in the posterior pharyngeal wall



Investigation

Manometric studies

Barium swallow



Anterior triangles

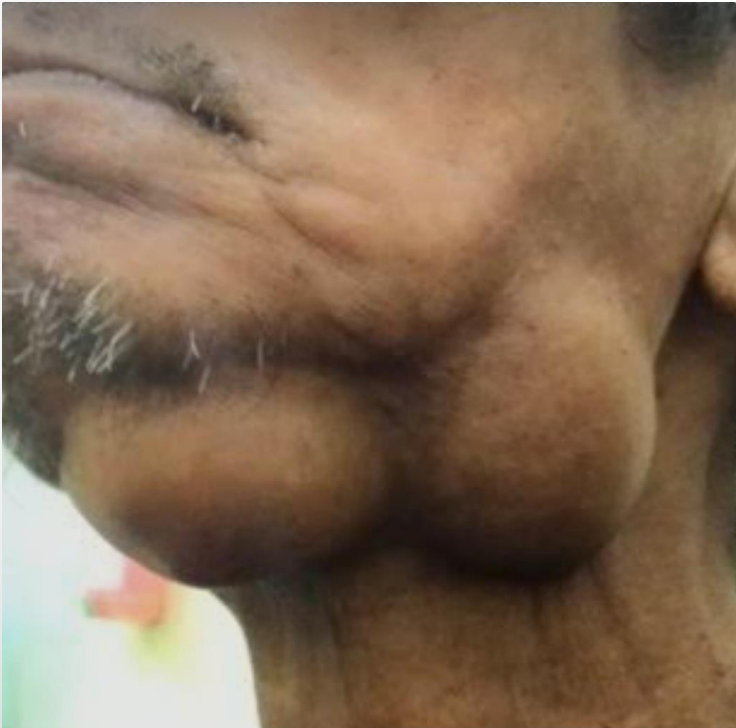Submandibular

Muscular

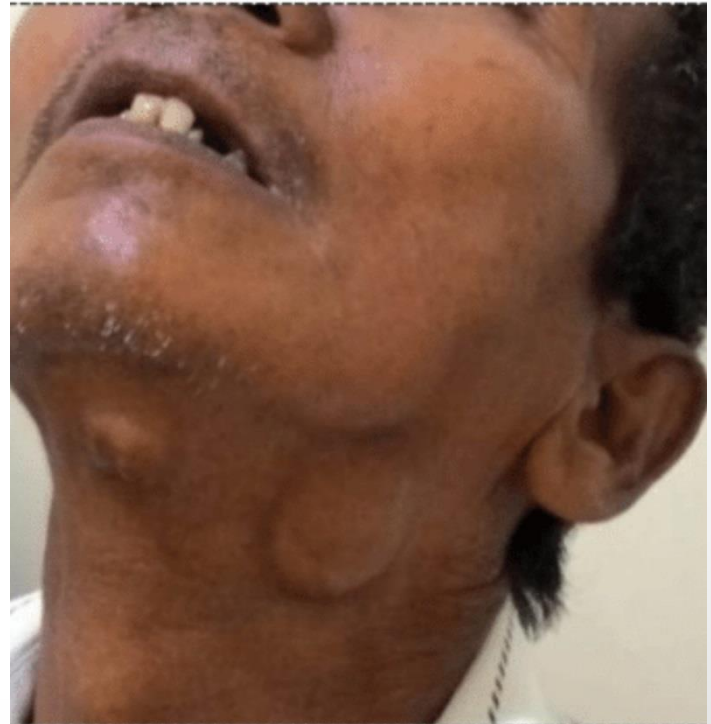
Carotid

Submandibular swellings

Enlargement of submandibular lymph node before treatment

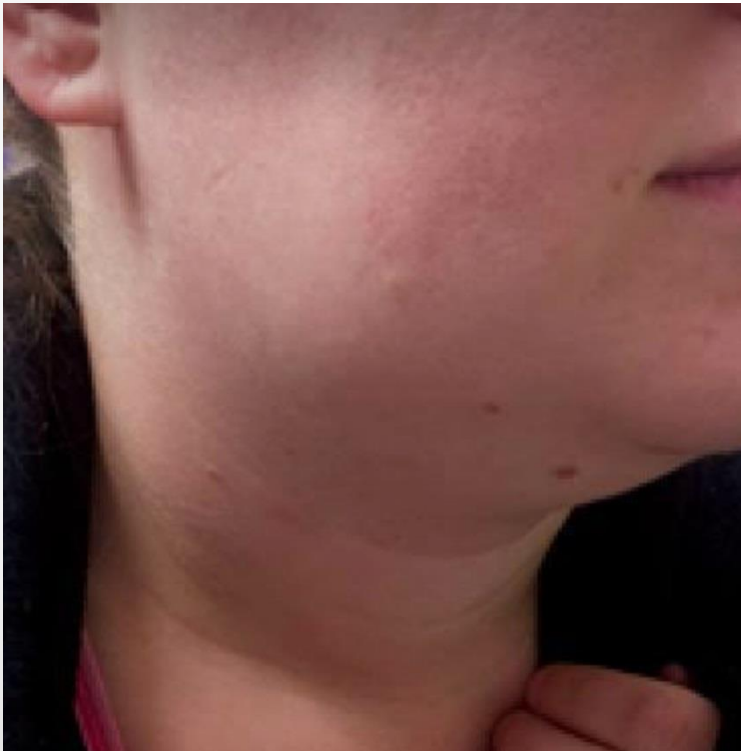

Submandibular lymph nodes after 6 months of treatment (the lymph nodes shrunk significantly)

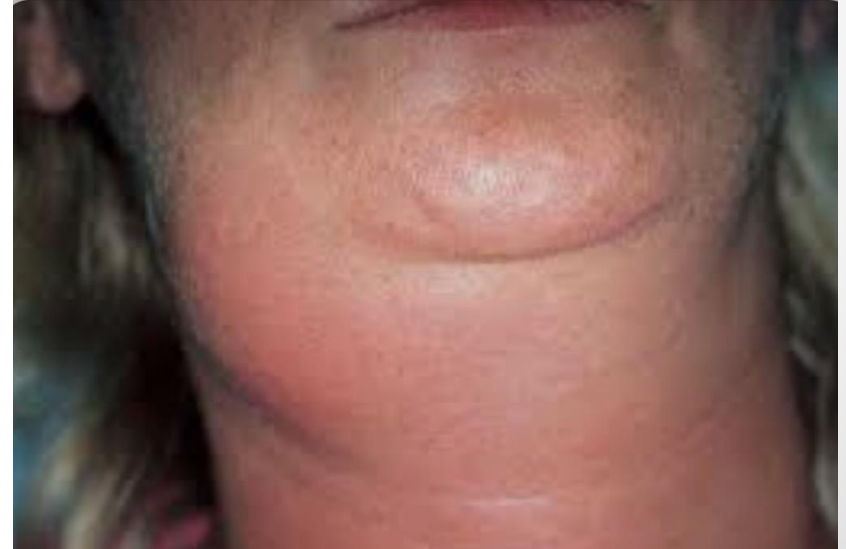

Sialadenitis

Acute submandibular
sialadenitis

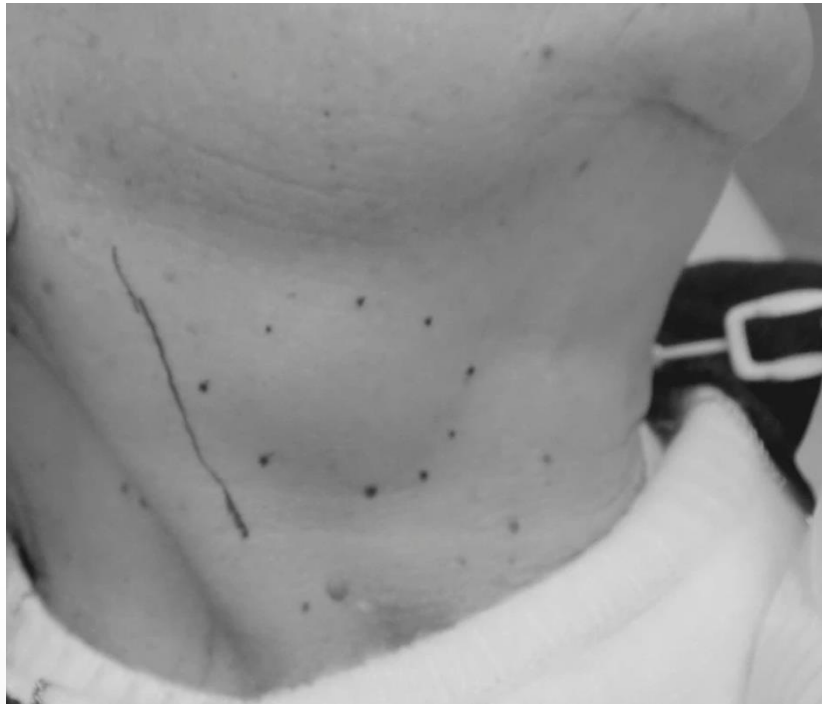

Submandibular
sialadenitis : swelling at
the angle of mandible
and the neck



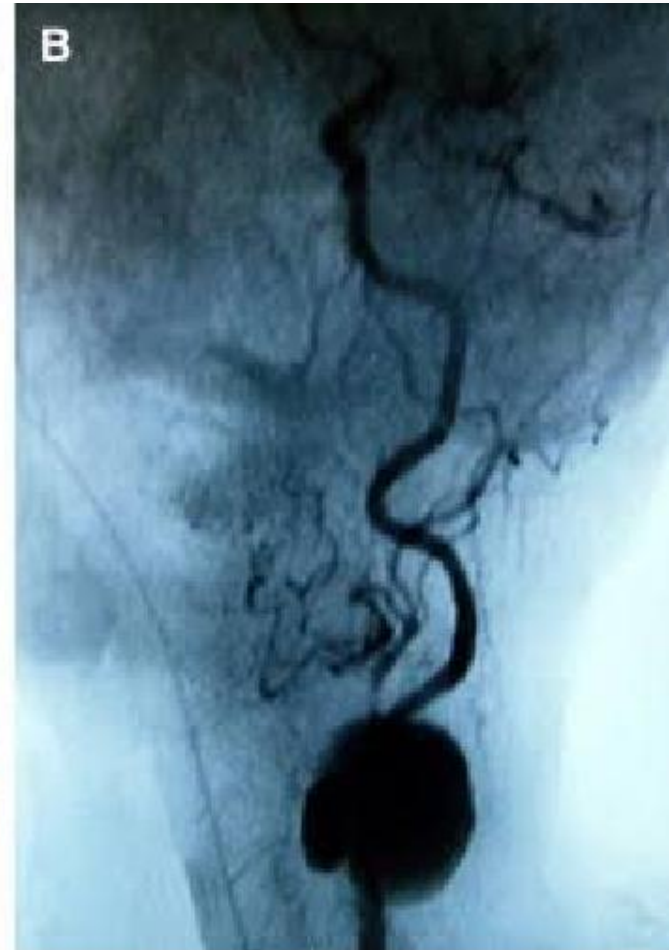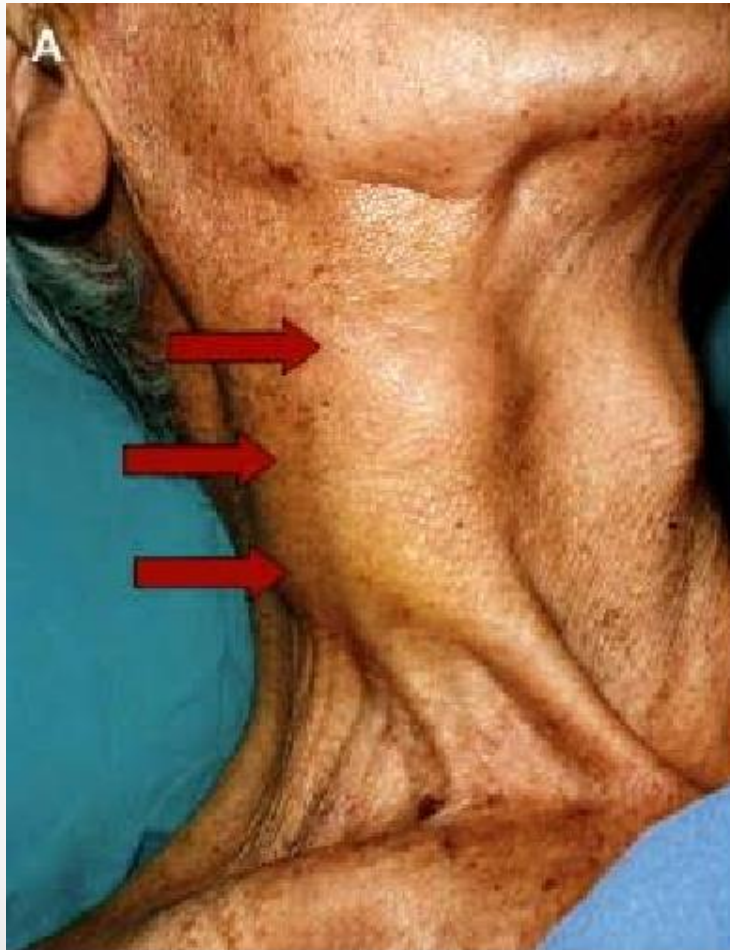
Metastasis

Submandibular lymph node metastasis of occult thyroid carcinoma first suspected to be salivary gland (elastic _soft _movable tumour at the right mandibular area



Carotid triangle

{Carotid aneurysm}



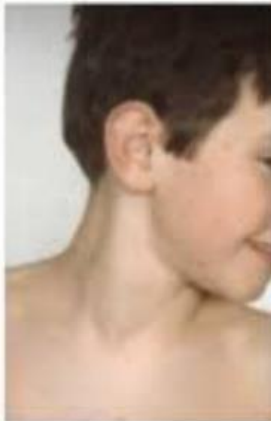Branchial Cyst

Branchial cleft cysts are congenital epithelial cysts

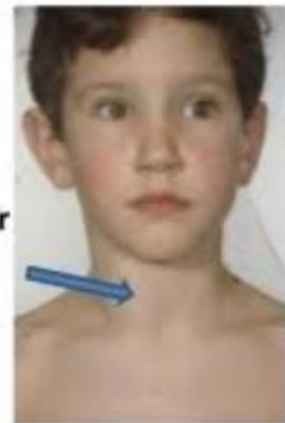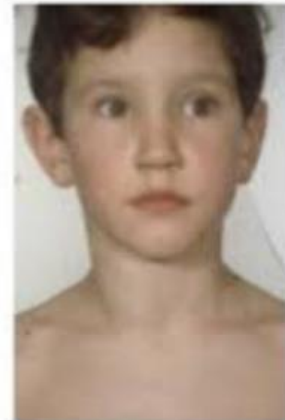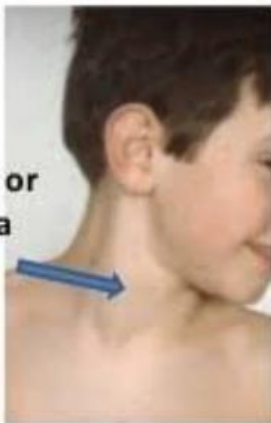Present on the lateral part of the neck

Painless, fluctuant mass in anterior triangle often behind SCM muscle

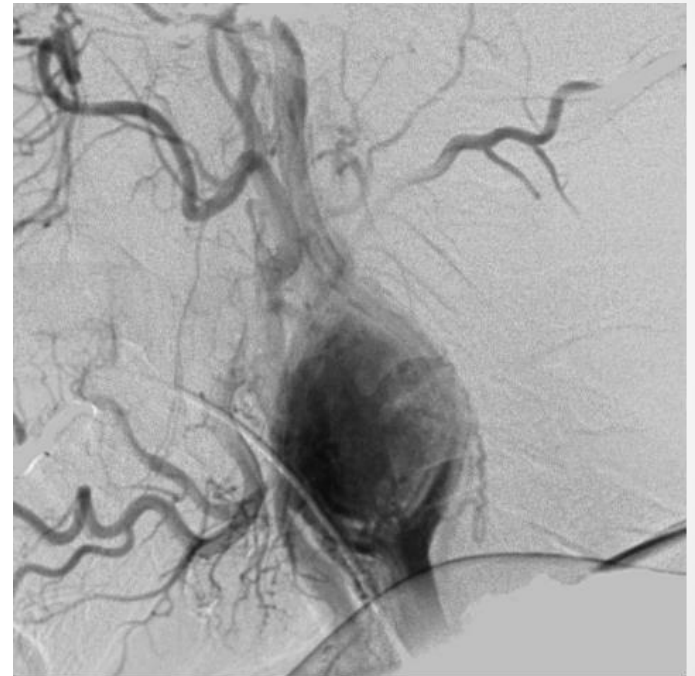
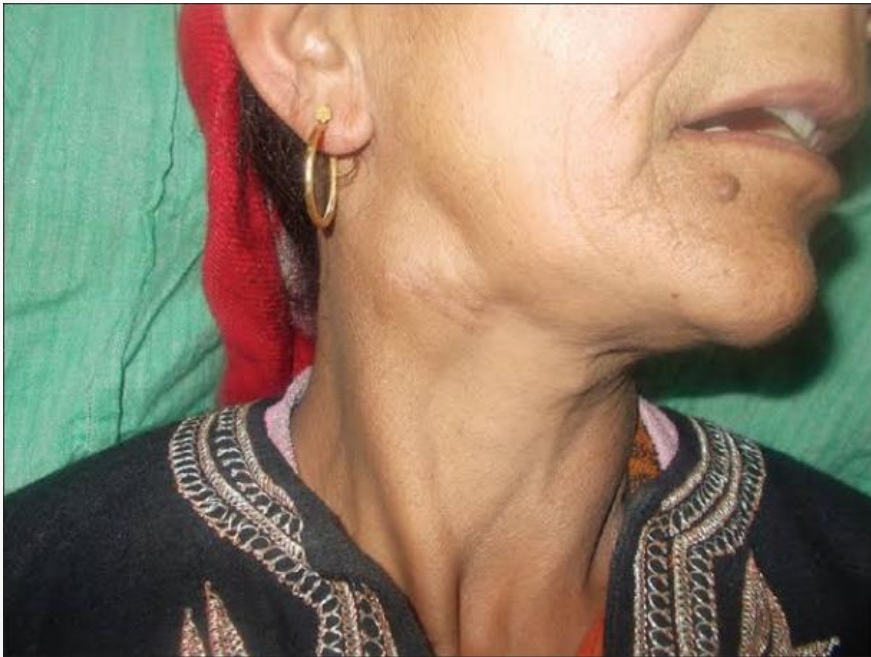Sinus / fistula on anterior border of SCM at junction of middle and lower 1/3
Often VERY tiny



Sinus or fistula



Carotid body tumor

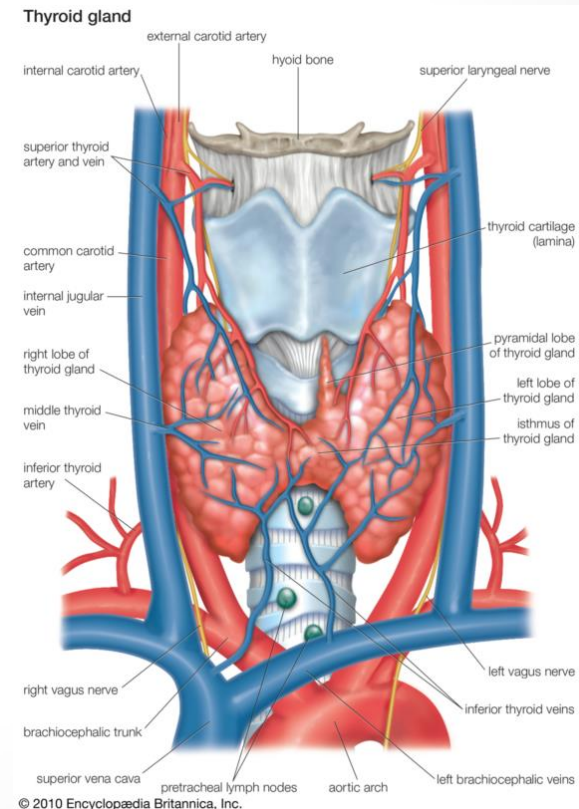
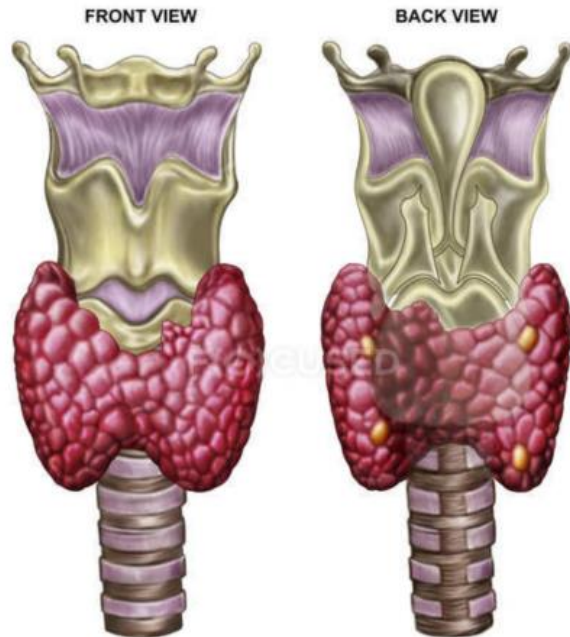


Muscular triangle

{Enlarged thyroid gland}

Anatomy •

{parts-weight-level-Artrialsupply-venous and
lymphatic drainge -nerves} •

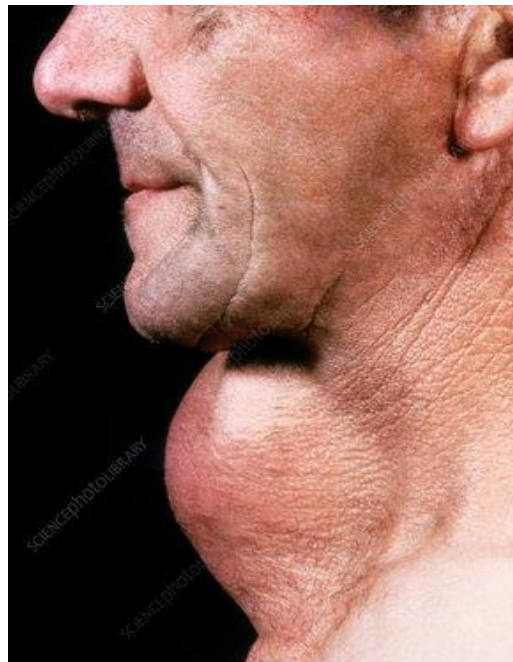


Goiter

Simple : physiological

Coolliodal-SNG

{incidence-aetiology-pathogens-CP-fate-treatment}



A red pushpin is pinned to the top center of the yellow sticky note.

THANK
You! 😊